




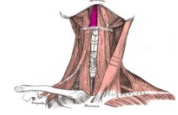
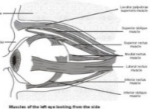





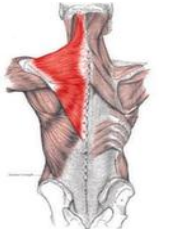

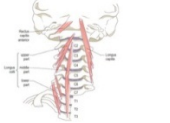
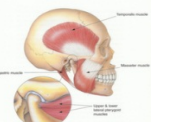
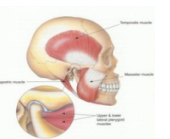
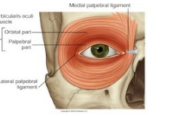



# Muscle List


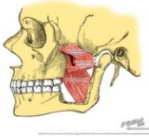
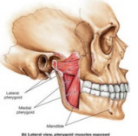
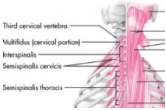
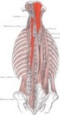


By: CellQuicken


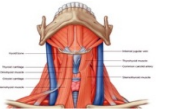
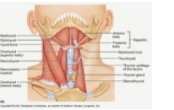


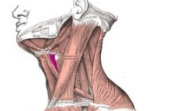
Picture	Name	Description
<b>HEAD &amp; NECK</b>		
	Buccinator	Its purpose is to pull back the angle of the mouth and to flatten the cheek area, which aids in holding the cheek to the teeth during chewing. This action causes the muscle to keep food pushed back on the occlusal surface of the posterior teeth, as when a person chews. By keeping the food in the correct position when chewing, the buccinator assists the muscles of mastication
	Constrictor Pharyngeus Medius	As soon as the bolus of food is received in the pharynx, the elevator muscles relax, the pharynx descends, and the constrictors contract upon the bolus, and convey it downward into the esophagus. They also have respiratory mechanical effects.
	Cricooarytenoideus Lateralis	The lateral cricoarytenoid (also anterior cricoarytenoid) muscles extend from the lateral cricoid cartilage to the muscular process of the arytenoid cartilage. By rotating the arytenoid cartilages medially, these muscles adduct the vocal cords and thereby close the rima glottidis, protecting the airway.
	Depressor Septi	The depressor septi is a direct antagonist of the other muscles of the nose, drawing the ala of the nose downward, and thereby constricting the aperture of the nares. Works like the alar part of the nasalis muscle.
	Digastric	The digastric muscle (also digastricus) (named digastric as it has two bellies) is a small muscle located under the jaw. When the digastric muscle contracts, it acts to elevate the hyoid bone. If the hyoid is being held in place (by the infrahyoid muscles), it will tend to depress the mandible (open the mouth).
	Geniohyoid	The geniohyoid muscle brings the hyoid bone forward and upwards. This dilates the upper airway, assisting respiration. During the first act of deglutition, when the mass of food is being driven from the mouth into the pharynx, the hyoid bone, and with it the tongue, is carried upward and forward by the anterior bellies of the Digastrici, the Mylohyoidei, and Geniohyoidei.
	Levator Palpebrae	The levator palpebrae superioris (Latin for: elevating muscle of upper eyelid) is the muscle in the orbit that elevates the superior (upper) eyelid

	<p><b>Rectus Inferior Bulbi</b></p>	<p>The inferior rectus muscle, is shown in this superior view of the eye, along with its axis of rotation. The other muscle is the superior oblique muscle, which angles around the trochlea. Six extraocular muscles facilitate eye movement. These muscles arise from the common tendinous ring in the orbit, the eye cavity, and attach to the eyeball. The six muscles are the lateral, medial, inferior and superior rectus muscles, and the inferior and superior oblique muscles. The muscles, when contracting, cause movement of the eyeball, by pulling the eyeball towards the muscle. For example, the lateral rectus is on the lateral side of the eyeball. When it contracts, the eyeball moves so that the pupil looks outwards. The medial rectus causes the eyeball to look inwards; the inferior rectus downwards and the superior rectus upwards. The superior oblique muscle and inferior oblique muscle attach at angles to the eyeball.</p>
	<p><b>Rectus Lateralis Bulbi</b></p>	
	<p><b>Rectus Medialis Bulbi</b></p>	<p>The lateral rectus muscle is a muscle in the orbit. It is one of six extraocular muscles that control the movements of the eye (abduction in this case). Its function is to bring the pupil away from the midline of the body. Six extraocular muscles facilitate eye movement. These muscles arise from the common tendinous ring in the orbit, the eye cavity, and attach to the eyeball. The six muscles are the lateral, medial, inferior and superior rectus muscles, and the inferior and superior oblique muscles. The muscles, when contracting, cause movement of the eyeball, by pulling the eyeball towards the muscle. For example, the lateral rectus is on the lateral side of the eyeball. When it contracts, the eyeball moves so that the pupil looks outwards. The medial rectus causes the eyeball to look inwards; the inferior rectus downwards and the superior rectus upwards. The superior oblique muscle and inferior oblique muscle attach at angles to the eyeball.</p>
	<p><b>Rectus Superior Bulbi</b></p>	
	<p><b>Levator Scapula</b></p>	<p>In human anatomy, the levator scapulae is a skeletal muscle situated at the back and side of the neck. As the name suggests, its main function is to lift the shoulder blade.</p>






	<p><b>Upper Trapezius</b></p>	<p>In human anatomy, the trapezius is a large superficial muscle that extends longitudinally from the occipital bone to the lower thoracic vertebrae and laterally to the spine of the scapula (shoulder blade). Its functions are to move the scapulae and support the arm. The trapezius has three functional regions: the superior region (descending part), which supports the weight of the arm; the intermediate region (transverse part), which retracts the scapulae; and the inferior region (ascending part), which medially rotates and depresses the scapulae.</p>
	<p><b>Longus Capitis</b></p>	<p>The longus capitis muscle (rectus capitis anticus major), broad and thick above, narrow below, arises by four tendinous slips, from the anterior tubercles of the transverse processes of the third, fourth, fifth, and sixth cervical vertebrae, and ascends, converging toward its fellow of the opposite side, to be inserted into the inferior surface of the basilar part of the occipital bone. It is innervated by a branch of cervical plexus. Longus capitis has several actions: acting unilaterally, to: * flex the head and neck laterally, * rotate the head ipsilaterally, acting bilaterally: * flex the head and neck</p>
	<p><b>Longus Colli</b></p>	<p>It is commonly injured in rear end whiplash injuries, usually resulting from a car crash. This muscle is in front of the spine and is thought by some scientists that it may cause some whiplash patients to have an unnatural lack of curvature in the patients' neck.</p>
	<p><b>Masseter</b></p>	<p>The action of the muscle during bilateral contraction of the entire muscle is to elevate the mandible, raising the lower jaw. Elevation of the mandible occurs during the closing of the jaws. The most obvious muscle of mastication is the masseter muscle since it is the most superficial and one of the strongest.</p>
	<p><b>Temporalis</b></p>	<p>The temporal muscle, also known as the temporalis, is one of the muscles of mastication. It is a broad, fan-shaped muscle on each side of the head that fills the temporal fossa, superior to the zygomatic arch so it covers much of the temporal bone. If the entire muscle contracts, the main action is to elevate the mandible, raising the lower jaw. Elevation of the mandible occurs during the closing of the jaws. If only the posterior part contracts, the muscle moves the lower jaw backward. Moving the lower jaw backward causes retraction of the mandible. Retraction of the jaw often accompanies the closing of the jaws.</p>
	<p><b>Orbicularis Oculi</b></p>	<p>The orbicularis oculi is a muscle in the face that closes the eyelids. The muscle acts to close the eye and is the only muscle capable of doing so. Loss of function for any reason results in an inability to close the eye, necessitating eye drops at the minimum to removal of the eye in extreme cases.</p>
	<p><b>Orbicularis Oris</b></p>	<p>In human anatomy, the orbicularis oris muscle is a complex of muscles in the lips that encircle the mouth. It is also one of the muscles used in the playing of all brass instruments and some woodwind instruments. This muscle closes the mouth and puckers the lips when it contracts.</p>



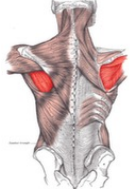




	<p><b>Platysma</b></p>	<p>When the entire platysma is in action it produces a slight wrinkling of the surface of the skin of the neck in an oblique direction. Its anterior portion, the thickest part of the muscle, depresses the lower jaw; it also serves to draw down the lower lip and angle of the mouth in the expression of melancholy, i.e. grimacing.</p>
	<p><b>Pterygoid External Lateralis</b></p>	<p>The primary function of the lateral pterygoid muscle is to pull the head of the condyle out of the mandibular fossa along the articular eminence to protrude the mandible. A concerted effort of the lateral pterygoid muscles acts in helping lower the mandible and open the jaw whereas unilateral action of a lateral pterygoid produces contralateral excursion (a form of mastication), usually performed in concert with the medial pterygoids. Unlike the other three muscles of mastication, the lateral pterygoid is the only muscle of mastication that assists in depressing the mandible (opening the jaw). At the beginning of this action it is assisted by the digastric, mylohyoid and geniohyoid muscles.</p>
	<p><b>Pterygoid Internal Medialis</b></p>	<p>Elevation of the mandible (closes the jaw). Minor contribution to protrusion of the mandible. Assistance in mastication. Excursion of the mandible; contralateral excursion occurs with unilateral contraction.</p>
	<p><b>Interspinales (cervical)</b></p>	<p>The Interspinales are short muscular fasciculi, placed in pairs between the spinous processes of the contiguous vertebræ, one on either side of the interspinal ligament. In the cervical region they are most distinct, and consist of six pairs, the first being situated between the axis and third vertebra, and the last between the seventh cervical and the first thoracic. They are small narrow bundles, attached, above and below, to the apices of the spinous processes. In the thoracic region, they are found between the first and second vertebræ, and sometimes between the second and third, and between the eleventh and twelfth. In the lumbar region there are four pairs in the intervals between the five lumbar vertebræ. There is also occasionally one between the last thoracic and first lumbar, and one between the fifth lumbar and the sacrum.</p>
	<p><b>Semispinalis Capitis</b></p>	<p>The semispinalis capitis (complexus) is situated at the upper and back part of the neck, deep to the splenius, and medial to the longissimus cervicis and capitis. It is part of the transversospinales muscle group. Extends and hyperextends the neck. Rotates head and neck to opposite sides.</p>
	<p><b>Semispinalis Cervicis</b></p>	<p>The semispinalis cervicis (semispinalis colli), arises by a series of tendinous and fleshy fibers from the transverse processes of the upper five or six thoracic vertebrae, and is inserted into the cervical spinous processes, from the axis to the fifth inclusive. The fasciculus connected with the axis is the largest, and is chiefly muscular in structure</p>
	<p><b>Splenius Capitis</b></p>	<p>The splenius capitis is a broad, straplike muscle in the back of the neck. It pulls on the base of the skull from the vertebrae in the neck and upper thorax. It is involved in simple movements such as shaking the head.</p>


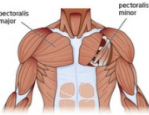
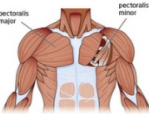
	<p><b>Splenius Cervicis</b></p>	<p>The function of the splenius cervicis muscle is extension of the cervical spine, rotation to the ipsilateral side and lateral flexion to the ipsilateral side. Extend the head &amp; neck,</p>
	<p><b>Sternohyoid</b></p>	<p>The sternohyoid muscle is a thin, narrow muscle attaching the hyoid bone to the sternum, one of the paired strap muscles of the infrahyoid muscles serving to depress the hyoid bone</p>
	<p><b>Sternothyroid</b></p>	<p>It arises from the posterior surface of the manubrium sterni, below the origin of the Sternohyoideus, and from the edge of the cartilage of the first rib, and sometimes that of the second rib, it is inserted into the oblique line on the lamina of the thyroid cartilage. This muscle is in close contact with its fellow at the lower part of the neck, but diverges somewhat as it ascends; it is occasionally traversed by a transverse or oblique tendinous inscription.</p>
	<p><b>Stylohyoid</b></p>	<p>The stylohyoid muscle is a slender muscle, lying anterior, and superior of the posterior belly of the digastric muscle. It shares this muscle's innervation by the facial nerve and functions to draw the hyoid bone backwards and elevate the tongue. When contracted, it elevates the hyoid, this action is primarily brought about during swallowing.</p>
	<p><b>Thyroarytenoideus</b></p>	<p>The thyroarytenoid muscle, consisting of two parts having different attachments and different directions, are rather complicated as regards their action. Their main use is to draw the arytenoid cartilages forward toward the thyroid, and thus relax and shorten the vocal folds. But, owing to the connection of the deeper portion with the vocal fold, this part, if acting separately, is supposed to modify its elasticity and tension, while the lateral portion rotates the arytenoid cartilage inward, and thus narrows the rima glottidis by bringing the two vocal folds together.</p>
	<p><b>Thyrohyoid</b></p>	<p>Elevates thyroid, depresses hyoid bone</p>

## CHEST & UPPER BACK

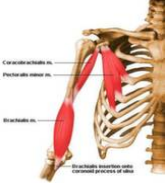
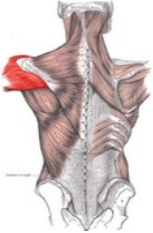
	<p><b>Trapezius</b></p>	<p>Contraction of the trapezius muscle can have two effects: movement of the scapulae when the spinal origins are stable, and movement of the spine when the scapulae are stable. Its main function is to stabilize and move the scapula. Scapular movements. The upper and lower fibres tend to rotate the scapula around the Sternoclavicular articulation so that the acromion and inferior angles move up and the medial border moves down. This rotation is in the opposite direction to that produced by levator scapulae and the rhomboids. The middle fibres retract the scapula. Spinal movements. When the scapulae are stable a co:contraction of both sides can extend the neck.</p>
	<p><b>Latissimus Dorsi</b></p>	<p>The latissimus dorsi is responsible for extension, adduction, transverse extension also known as horizontal abduction, flexion from an extended position, and (medial) internal rotation of the shoulder joint. It also has a synergistic role in extension and lateral flexion of the lumbar spine. Most latissimus dorsi exercises concurrently recruit the teres major, posterior fibres of the deltoid, long head of the triceps brachii, among numerous other stabilizing muscles. Compound exercises for the 'lats' typically involve elbow flexion and tend to recruit the biceps brachii, brachialis, and brachioradialis for this function. Depending on the line of pull, the trapezius muscles can be recruited as well; horizontal pulling motions such as rows recruit both latissimus dorsi and trapezius heavily.</p>
	<p><b>Rhomboid minor</b></p>	<p>Together with the rhomboid major, the rhomboid minor retracts the scapula when trapezius is contracted. Acting as an antagonist to the trapezius, the rhomboid major and minor elevate the medial border of the scapula medially and upward, working in tandem with the levator scapulae (Shoulder blades) muscle to rotate the scapulae downward. While other shoulder muscles are active, the rhomboid major and minor stabilize the scapula.</p>
	<p><b>Rhomboid major</b></p>	<p>The rhomboid major helps to hold the scapula (and thus the upper limb) onto the ribcage. Other muscles that perform this function include the serratus anterior and pectoralis minor. Both rhomboids (major and minor) also act to retract the scapula, pulling it towards the vertebral column. The rhomboids work collectively with the levator scapulae muscles to elevate the medial border of the scapula, downwardly rotating the scapula with respect to the glenohumeral joint. Antagonists to this function (upward rotators of the scapulae) are the serratus anterior and upper and lower fibers of the trapezius. If the lower fibers are inactive, the serratus anterior and upper trapezii work in tandem with rhomboids and levators to elevate the entire scapula.</p>
	<p><b>Serratus Anterior</b></p>	<p>The muscle is inserted along the medial border of the scapula between the superior and inferior angles along with being inserted along the thoracic vertebrae. The muscle is divided into three named parts depending on their points of insertions: the serratus anterior superior is inserted near the superior angle the serratus anterior intermediate is inserted along the medial border the serratus anterior inferior is inserted near the inferior angle. All three parts described above pull the scapula forward around the thorax, which is essential for anteversion of the arm. As such, the muscle is an antagonist to the rhomboids. However, when the inferior and superior parts act together, they keep the scapula pressed against the thorax together with the rhomboids and therefore these parts also act as synergists to the rhomboids.</p> <p>The inferior part can pull the lower end of the scapula laterally and forward and thus rotates the scapula to make elevation of the arm possible. Additionally, all three parts can lift the ribs when the shoulder girdle is fixed, and thus assist in respiration. The serratus anterior is occasionally called the 'big swing muscle' or 'boxer's muscle' because it is largely responsible for the protraction of the scapula — that is, the pulling of the scapula forward and around the rib cage that occurs when someone throws a punch. The serratus anterior also plays an important role in the upward rotation of the scapula, such as when lifting a weight overhead. It performs this in sync with the upper and lower fibers of the trapezius.</p>




	<p><b>Subclavius</b></p>	<p>The subclavius is a small triangular muscle, placed between the clavicle and the first rib. The subclavius depresses the shoulder, carrying it downward and forward. It draws the clavicle inferiorly as well as anteriorly.</p>
	<p><b>Supraspinatus</b></p>	<p>It is one of the four rotator cuff muscles and also abducts the arm at the shoulder. The spine of the scapula separates the supraspinatus muscle from the infraspinatus muscle, which originates below the spine. Contraction of the supraspinatus muscle leads to abduction of the arm at the shoulder joint. It is the main agonist muscle for this movement during the first 10:15 degrees of its arc. Beyond 30 degrees the deltoid muscle becomes increasingly more effective at abducting the arm and becomes the main propagator of this action. The supraspinatus muscle is one of the musculotendinous support structures called the rotator cuff that surround and enclose the shoulder. It helps to resist the inferior gravitational forces placed across the shoulder joint due to the downward pull from the weight of the upper limb. The supraspinatus also helps to stabilize the shoulder joint by keeping the head of the humerus firmly pressed medially against the glenoid fossa[disambiguation needed] of the scapula. Without a functioning supraspinatus, the physician must start abducting the patient's arm and eventually the patient will be able to finish abduction if the deltoid is functional, which is common because the supraspinatus is innervated by the suprascapular nerve from the superior/upper trunk of the brachial plexus. The deltoid is innervated more distally by the axillary nerve, which arises from the posterior cord of the brachial plexus.</p>
	<p><b>Infraspinatus</b></p>	<p>The infraspinatus is the main external rotator of the shoulder. When the arm is fixed, it abducts the inferior angle of the scapula. Its synergists are teres minor and the deltoid. The infraspinatus and teres minor rotate the head of the humerus outward (external, or lateral, rotation); they also assist in carrying the arm backward (extension of the glenohumeral joint). Additionally, the infraspinatus reinforces the capsule of the shoulder joint</p>
	<p><b>Teres minor</b></p>	<p>The infraspinatus and teres minor attach to head of the humerus; as part of the rotator cuff they help hold the humeral head in the glenoid cavity of the scapula. They work in tandem with the posterior deltoid to externally (laterally) rotate the humerus, as well as perform transverse abduction, extension and transverse extension.</p>
	<p><b>Subscapularis</b></p>	<p>The subscapularis rotates the head of the humerus medially (internal rotation); when the arm is raised, it draws the humerus forward and downward. It is a powerful defense to the front of the shoulder: joint, preventing displacement of the head of the humerus.</p>




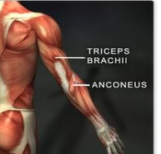


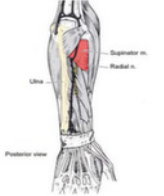



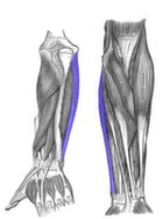
	<p><b>Teres major</b></p>	<p>The teres major is a medial rotator and adductor of the humerus and assists the latissimus dorsi in drawing the previously raised humerus downward and backward (extension, but not hyper extension). It also helps stabilize the humeral head in the glenoid cavity.</p>
	<p><b>Pectoralis minor</b></p>	<p>The pectoralis minor is a thin, triangular muscle, situated at the upper part of the chest, beneath the pectoralis major in the human body. The pectoralis minor depresses the point of the shoulder, drawing the scapula inferior and medial, towards the thorax, and throwing its inferior angle posteriorly</p>
	<p><b>Pectoralis Major</b></p>	<p>The pectoralis major (from Latin: pectus, breast) is a thick, fan-shaped muscle, situated at the chest (anterior) of the human body. It makes up the bulk of the chest muscles in the male and lies under the breast in the female. Underneath the pectoralis major is the pectoralis minor, a thin, triangular muscle. The pectoralis major has four actions which are primarily responsible for movement of the shoulder joint. The first action is flexion of the humerus, as in throwing a ball side:arm, and in lifting a child. Secondly, it adducts the humerus, as when flapping the arms. Thirdly, it rotates the humerus medially, as occurs when arm:wrestling. The pectoralis major is also responsible for keeping the arm attached to the trunk of the body. It has two different parts which are responsible for different actions. The clavicular part is close to the deltoid muscle and contributes to flexion, horizontal adduction, and inward rotation of the humerus. When at an approximately 110 degree angle,[citation needed] it contributes to adduction of the humerus. The sternocostal part is antagonistic to the clavicular part contributing to downward and forward movement of the arm and inward rotation when accompanied by adduction. The sternal fibers can also contribute to extension, but not beyond anatomical position.</p>

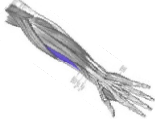


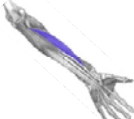
## ARM & HAND



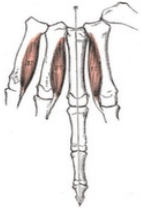



	<p><b>Coracobrachialis</b></p>	<p>The coracobrachialis is the smallest of the three muscles that attach to the coracoid process of the scapula. The action of the coracobrachialis is to flex and medially rotate the arm. Also, the coracobrachialis resists deviation of the arm from the frontal plane during abduction. Therefore, the contraction of the coracobrachialis leads to two distinct movements at the shoulder joint. It both draws the humerus forward, causing shoulder flexion, and draws the humerus toward the torso, causing shoulder adduction. To a smaller extent, it also turns the humerus inwards, causing inward rotation. Another important function of the coracobrachialis is the stabilization of the humeral head within the shoulder joint, especially when the arm is hanging freely at a person's side.</p>
	<p><b>Brachialis</b></p>	<p>The brachialis (brachialis anticus) is a muscle in the upper arm that flexes the elbow joint. It lies deeper than the biceps brachii, and is a synergist that assists the biceps brachii in flexing at the elbow. It makes up part of the floor of the region known as the cubital fossa. Unlike the biceps, the brachialis does not insert on the radius, and therefore cannot participate in pronation and supination of the forearm. It flexes the elbow joint.</p>
	<p><b>Deltoid</b></p>	<p>When all its fibers contract simultaneously, the deltoid is the prime mover of arm abduction along the frontal plane. The arm must be medially rotated for the deltoid to have maximum effect[citation needed]. This makes the deltoid an antagonist muscle of the pectoralis major and latissimus dorsi during arm adduction. The posterior fibers are strongly involved in transverse extension particularly as the latissimus dorsi is very weak in strict transverse extension. Other transverse extensors, the infraspinatus and teres minor, also work in tandem with the posterior deltoid as external (lateral) rotators, antagonists to strong internal rotators like the pecs and lats. The posterior deltoid is also the primary shoulder hyperextensor, more so than the long head of the triceps which also assists in this function.</p>
	<p><b>Deltoid</b></p>	<p>When all its fibers contract simultaneously, the deltoid is the prime mover of arm abduction along the frontal plane. The arm must be medially rotated for the deltoid to have maximum effect[citation needed]. This makes the deltoid an antagonist muscle of the pectoralis major and latissimus dorsi during arm adduction. The anterior fibers are involved in shoulder abduction when the shoulder is externally rotated. The anterior deltoid is weak in strict transverse flexion but assists the pectoralis major during shoulder transverse flexion / shoulder flexion (elbow slightly inferior to shoulders). The anterior deltoid also works in tandem with the subscapularis, pecs and lats to internally (medially) rotate the humerus.</p>






	<p><b>Biceps Brachii</b></p>	<p>In human anatomy, the biceps brachii commonly known as the biceps, is a two-headed muscle that lies on the upper arm between the shoulder and the elbow. Both heads arise on the scapula and join to form a single muscle belly which is attached to the upper forearm. While the biceps crosses both the shoulder and elbow joints, its main function is at the latter where it flexes the elbow and supinates the forearm. Both these movements are used when opening a bottle with a corkscrew: first biceps unscrews the cork (supination), then it pulls the cork out. Green = Shorthead; Red = Long Head. The biceps is tri:articulate, meaning that it works across three joints. The most important of these functions is to supinate the forearm and flex the elbow. These joints and the associated actions are listed as follows in order of importance:</p> <p>Proximal radioulnar joint (upper forearm) – Contrary to popular belief, the biceps brachii is not the most powerful flexor of the forearm, a role which actually belongs to the deeper brachialis muscle. The biceps brachii functions primarily as a powerful supinator of the forearm (turns the palm upwards). This action, which is aided by the supinator muscle, requires the elbow to be at least partially flexed. If the elbow, or humeroulnar joint, is fully extended, supination is then primarily carried out by the supinator muscle. Humeroulnar joint (elbow) – The biceps brachii also functions as an important flexor of the forearm, particularly when the forearm is supinated. Functionally, this action is performed when lifting an object, such as a bag of groceries or when performing a biceps curl. When the forearm is in pronation (the palm faces the ground), the brachialis, brachioradialis, and supinator function to flex the forearm, with minimal contribution from the biceps brachii. Glenohumeral joint (shoulder) – Several weaker functions occur at the glenohumeral, or shoulder, joint. The biceps brachii weakly assists in forward flexion of the shoulder joint (bringing the arm forward and upwards). It may also contribute to abduction (bringing the arm out to the side) when the arm is externally (or laterally) rotated. The short head of the biceps brachii also assists with horizontal adduction (bringing the arm across the body) when the arm is internally (or medially) rotated. Finally, the short head of the biceps brachii, due to its attachment to the scapula (or shoulder blade), assists with stabilization of the shoulder joint when a heavy weight is carried in the arm.</p>
	<p><b>Triceps</b></p>	<p>The triceps brachii muscle (Latin for :three:headed arm muscle:;) is the large muscle on the back of the upper limb of many vertebrates. It is the muscle principally responsible for extension of the elbow joint (straightening of the arm). Three different colors represent three different bundles which compose triceps. Red = Long head. The triceps is an extensor muscle of the elbow joint and an antagonist of the biceps and brachialis muscles. It can also fixate the elbow joint when the forearm and hand are used for fine movements, e.g., when writing. It has been suggested that the long head fascicle is employed when sustained force generation is demanded, or when there is a need for a synergistic control of the shoulder and elbow or both. The lateral head is used for movements requiring occasional high:intensity force, while the medial fascicle enables more precise, low:force movements. With its origin on the scapula, the long head also acts on the shoulder joint and is also involved in retroversion and adduction of the arm.</p>
	<p><b>Articularis Cubiti</b></p>	<p>The Articularis cubiti muscle is a muscle of the elbow. It is considered by some sources to be a part of the triceps brachii muscle. It is also known as the :Subanconeus muscle:, for its relationship to the Anconeus muscle. It is classified as a muscle of the posterior brachium.</p>

	<p><b>Brachioradialis</b></p>	<p>The brachioradialis is a muscle of the forearm that flexes the forearm at the elbow. It is also capable of both pronation and supination, depending on the position of the forearm. It is attached to the distal styloid process of the radius by way of the brachioradialis tendon, and to the lateral supracondylar ridge of the humerus. The brachioradialis flexes the forearm at the elbow. When the forearm is pronated, the brachioradialis tends to supinate as it flexes. In a supinated position, it tends to pronate as it flexes. This also assists the biceps brachii. The brachioradialis is a stronger elbow flexor when the forearm is in a midposition between supination and pronation at the radioulnar joint. When pronated, the brachioradialis is more active during elbow flexion since the biceps brachii is in a mechanical disadvantage. With the insertion of the muscle so far from the fulcrum of the elbow, the brachioradialis does not generate as much joint torque as the brachialis or the biceps. It is effective mainly when those muscles have already partially flexed at the elbow. The brachioradialis flexes the forearm at the elbow, especially when quick movement is required and when a weight is lifted during slow flexion of the forearm. The muscle is used to stabilize the elbow during rapid flexion and extension while in a midposition, such as in hammering. The brachioradialis is synergistic with the brachialis and biceps brachii; the triceps brachii and anconeus are antagonistic</p>
	<p><b>Pronator Teres</b></p>	<p>The pronator teres is a muscle of the human body (located mainly in the forearm) that, along with the pronator quadratus muscle, serves to pronate the forearm (turning it so that the palm faces posteriorly when from the anatomical position). The pronator teres has two heads—humeral and ulnar. The humeral head, the larger and more superficial, arises from the medial supracondylar ridge immediately superior to the medial epicondyle of the humerus, and from the common flexor tendon (which arises from the medial epicondyle). The ulnar head is a thin fasciculus, which arises from the medial side of the coronoid process of the ulna, and joins the preceding at an acute angle. The median nerve enters the forearm between the two heads of the muscle, and is separated from the ulnar artery by the ulnar head. The muscle passes obliquely across the forearm, and ends in a flat tendon, which is inserted into a rough impression at the middle of the lateral surface of the body of the radius, just distal to the insertion of the supinator. The lateral border of the muscle forms the medial boundary of the triangular hollow known as the cubital fossa, which is situated anterior to the elbow. Pronator teres pronates the forearm, turning the hand posteriorly. If the elbow is flexed to a right angle, then pronator teres will turn the hand so that the palm faces inferiorly. It is assisted in this action by pronator quadratus. It also weakly flexes the elbow, or assists in flexion at the elbow when there is strong resistance.</p>
	<p><b>Pronator Quadratus</b></p>	<p>Pronator quadratus is a square shaped muscle on the distal forearm that acts to pronate (turn so the palm faces downwards) the hand. When pronator quadratus contracts, it pulls the lateral side of the radius towards the ulna, thus pronating the hand. Its deep fibers serve to keep the two bones in the forearm bound together.</p>
	<p><b>Anconeus</b></p>	<p>The anconeus muscle (or anconaeus/anconæus) is a small muscle on the posterior aspect of the elbow joint. Some consider anconeus to be a continuation of the triceps brachii muscle. Anconeus originates on the posterior surface of the lateral epicondyle of the humerus and is inserted on the ulna lateral to the olecranon from where it extends down on the dorsal side of the bone. It is partly blended in with the triceps, which it assists in extension of the forearm. It also stabilizes the elbow during pronation and supination and pulls slack out of the elbow joint capsule during extension to prevent impingement.</p>

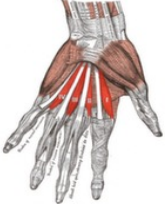


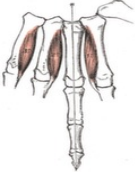

 <p>Supinator</p>	<p><b>Supinator</b></p>	<p>Supinator consists of two planes of fibers, between which the deep branch of the radial nerve lies. The two planes arise in common — the superficial one by tendinous (the initial portion of the muscle is actually just tendon) and the deeper by muscular fibers — from the supinator crest of ulna, the lateral epicondyle of humerus, the radial collateral ligament, and the annular radial ligament. Encircling the radius, supinator brings the hand into the supinated position. In contrast to the biceps brachii, it is able to do this in all positions of elbow flexion and extension. Supinator always acts together with biceps, except when the elbow joint is extended. It is the most active muscle in forearm supination during unresisted supination, while biceps becomes increasingly active with heavy loading. Supination strength decreases by 64% if supinator is disabled by, for example, injury.</p>
	<p><b>Palmaris Longus</b></p>	<p>The palmaris longus muscle can be palpated by touching the pads of the fifth finger and thumb whilst flexing the wrist. The tendon, if present, will be visible in the midline of the anterior wrist. Wrist flexor</p>
	<p><b>Flexor Carpi Radialis</b></p>	<p>Flexion and abduction at wrist. In anatomy, flexor carpi radialis is a muscle of the human forearm that acts to flex and (radial) abduct the hand.</p>
	<p><b>Flexor Carpi Ulnaris</b></p>	<p>The flexor carpi ulnaris (FCU) muscle is a muscle of the human forearm that acts to flex and adduct the hand. The tendon of flexor carpi ulnaris can be seen on the anterior of the distal forearm. On a person's distal forearm, right before the wrist, there will be either two or three tendons. The tendon of the flexor carpi ulnaris is the most medial (closest to the little finger) of these. The most lateral one is the tendon of flexor carpi radialis muscle, and the middle one, not always present, is the tendon of palmaris longus.</p>
	<p><b>Extensor Carpi Ulnaris</b></p>	<p>In human anatomy, the extensor carpi ulnaris is a skeletal muscle located on the ulnar side of the forearm. It acts to extend and adduct at the carpus/wrist. Being an extensor muscle, extensor carpi ulnaris is on the posterior side of the forearm. The extensor carpi ulnaris extends the wrist, but when acting alone inclines the hand toward the ulnar side; by its continued action it extends the elbow; joint. The muscle is a minor extensor of the carpus in carnivores, but has become a flexor in ungulates. In this case it is described as ulnaris lateralis. A common injury to the extensor carpi ulnaris is tennis elbow. This injury occurs in people that participate in activities requiring repetitive arm, elbow, and wrist, especially then they are tightly gripping an object. Some symptoms include pain when shaking hands or squeezing an object.</p>

	<p><b>Extensor Carpi Radialis Brevis</b></p>	<p>In human anatomy, extensor carpi radialis brevis is a muscle in the forearm that acts to extend and abduct the wrist. It is shorter and thicker than its namesake extensor carpi radialis longus which can be found above the proximal end of the extensor carpi radialis brevis. It is an extensor, and an abductor of the hand at the wrist joint. That is, it serves to manipulate the wrist so that the hand moves away from the palm and towards the thumb. The muscle, like all extensors of the forearm, can be strengthened by exercise that resist its extension. A wrist roller can be used and reverse wrist curls with dumbbells can be performed.</p>
	<p><b>Extensor Carpi Radialis Longus</b></p>	<p>The extensor carpi radialis longus is one of the five main muscles that control movements at the wrist. This muscle is quite long, starting on the lateral side of the humerus, and attaching to the base of the second metacarpal bone (metacarpal of the index finger). As the name suggests, this muscle is an extensor at the wrist joint and travels along the radial side of the arm, so will also abduct (radial abduction) the hand at the wrist. That is, it manipulates the wrist so as to move the hand towards the thumb (i.e., abduction — away from the mid:position of the hand) and away from the palmar side (i.e., extension—increased angle between the palm and the front of the forearm).</p>
	<p><b>Extensor Pollicis Longus</b></p>	<p>The extensor pollicis longus (EPL) is a skeletal muscle located dorsally on the forearm. It is much larger than the extensor pollicis brevis, the origin of which it partly covers, and acts to stretch the thumb together with this muscle. Extensor pollicis longus extends the terminal phalanx of the thumb. While abductor pollicis brevis and adductor pollicis, both attached to the extensor pollicis longus tendon, can extend the thumb's interphalangeal joint to the neutral position, only extensor pollicis longus can achieve full hyperextension at the interphalangeal joint. This complete extension at the interphalangeal joint is not possible, or considerably more difficult, with the carpal, carpometacarpal, and metacarpophalangeal joints simultaneously extended. Likewise, flexion at the interphalangeal joint by flexor pollicis longus is considerably reduced in wrist flexion. It also applies an extensor force at the metacarpophalangeal joint together with the extensor pollicis brevis and extends and adducts at the carpometacarpal joint of the thumb.</p>
	<p><b>Extensor Pollicis Brevis</b></p>	<p>In human anatomy, the extensor pollicis brevis is a skeletal muscle on the dorsal side of the forearm. It lies on the medial side of, and is closely connected with, the abductor pollicis longus. In a close relationship to the abductor pollicis longus, the extensor pollicis brevis both extends and abducts the thumb</p>
	<p><b>Flexor Pollicis Longus</b></p>	<p>The flexor pollicis longus (FPL, Latin flexor, bender; pollicis, of the thumb; longus, long) is a muscle in the forearm and hand that flexes the thumb. It lies in the same plane as the flexor digitorum profundus. This muscle is unique to humans, being either rudimentary or absent in other primates. The flexor pollicis longus is a flexor of the phalanges of the thumb; when the thumb is fixed, it assists in flexing the wrist.[]</p>

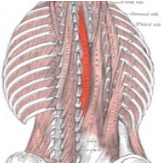
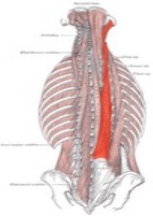
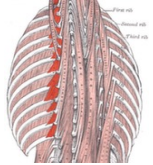
	<p><b>Abductor Pollicis Longus</b></p>	<p>The chief action of abductor pollicis longus is to abduct the thumb at the carpometacarpal joint, thereby moving the thumb anteriorly. It also assists in extending and rotating the thumb.</p>
	<p><b>Flexor Pollicis Brevis</b></p>	<p>The flexor pollicis brevis is a muscle in the hand that flexes the thumb. It is one of three thenar muscles. It has both a superficial part and a deep part. Flexes the thumb at the first metacarpophalangeal joint</p>
	<p><b>Interossei Pollicis (Palmaris first)</b></p>	<p>Adduction, flexion and extension of fingers. The palmar interosseous muscles adduct the fingers towards the middle finger. This is in contrast to the dorsal interossei, which abduct the fingers away from the middle finger. In addition (like dorsal interossei) they flex the finger at the metacarpo:phalangeal joint and extend the finger at the interphalangeal joint and thus assist the lumbricals. The palmar interossei, together with the dorsal interossei and the lumbricals, are active components of the finger's extensor mechanism. Fibers from some of the interossei contribute directly to the extensor hoods that wrap around the proximal phalanges while other fibers may contribute to the central tendon and lateral bands of the mechanism. All three intrinsic groups of muscles pass palmar to the axis of the metacarpophalangeal joints and therefore contribute to flexion there. Extension at the interphalangeal joints cannot be produced by the extensor digitorum alone, but active contraction of one of the three aforementioned intrinsic groups will because of their direct contribution to the extensor mechanism.</p>
	<p><b>Opponens Pollicis</b></p>	<p>Opposition of the thumb is a combination of actions that allows the tip of the thumb to touch the tips of other fingers. The part of opposition that this muscle is responsible for is the flexion of the thumb's metacarpal at the first carpometacarpal joint. This specific action cups the palm. Many texts, for simplicity, use the term opposition to represent this component of true opposition. In order to truly oppose the thumb, the actions of a number of other muscles are needed at the thumb's metacarpophalangeal joint.</p>
	<p><b>Abductor Pollicis Brevis</b></p>	<p>The abductor pollicis brevis is a muscle in the hand that functions as an abductor of the thumb. Abduction of the thumb is defined as the movement of the thumb anteriorly, a direction perpendicular to the palm. The abductor pollicis brevis does this by acting across both the carpometacarpal joint and the metacarpophalangeal joint. It also assists in opposition and extension of the thumb.</p>
	<p><b>Adductor Pollicis</b></p>	<p>The adductor pollicis muscle is a muscle in the hand that functions to adduct the thumb. It has two heads: transverse and oblique. It is a fleshy, flat, triangular, and fan-shaped muscle deep in the thenar compartment beneath the long flexor tendons and the lumbrical muscles at the center of the palm. It overlies the metacarpal bones and the interosseous muscles. While adduction of the thumb (bringing it back into the plane of the palm of the hand from its previously abducted position) is mainly produced by the adductor pollicis, it can also bring the thumb to the side of the palm and index finger and the flexor pollicis brevis and the opponens pollicis help in thumb adduction. Transverse head: The transverse head (Latin: adductor transversus pollicis) is deeply seated. It is triangular, arising by a broad base from the lower two-thirds of the palmar surface of the third metacarpal bone; the fibers converge, to be inserted with the medial part of the flexor pollicis brevis and the oblique head into the ulnar side of the base of the proximal phalanx of the thumb.</p>


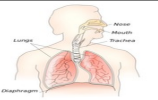


	<p><b>Extensor Digitorum Communis Manus</b></p>	<p>extension of hand, wrist and fingers:: The extensor digitorum muscle (also known as extensor digitorum communis) is a muscle of the posterior forearm present in humans and other animals. It extends the medial four digits of the hand. The extensor digitorum communis extends the phalanges, then the wrist, and finally the elbow. It acts principally on the proximal phalanges, the middle and terminal phalanges being extended mainly by the interossei and lumbricales. It tends to separate the fingers as it extends them.</p>
	<p><b>Extensor Digiti Minimi Manus</b></p>	<p>Abducts little finger: It is possible that the muscle contribute to extension of the middle phalanx of the little finger through its connection to finger's extensor mechanism. It plays an important role when the hand is grasping large objects with outspread fingers.</p>
	<p><b>Extensor Indicis Proprius</b></p>	<p>The extensor indicis extends the index finger, and by its continued action assists in extending (dorsiflexion) the wrist and the midcarpal joints. Because the index finger and little finger have separate extensors, these fingers can be moved more independently than the other fingers.</p>
	<p><b>Flexor Digitorum Superficialis</b></p>	<p>Flexor of fingers (primarily at proximal interphalangeal joints) The primary function of flexor digitorum superficialis is flexion of the middle phalanges of the fingers at the proximal interphalangeal joints, however under continued action it also flexes the metacarpophalangeal joints and wrist joint. To test flexor digitorum superficialis, one finger is flexed at the proximal interphalangeal joint against resistance, while the remaining three fingers are held fully extended (to inactivate flexor digitorum profundus).</p>
	<p><b>Flexor Digitorum Profundus Manus</b></p>	<p>The lumbricales are intrinsic muscles of the hand that flex the metacarpophalangeal joints and extend the interphalangeal joints. There are four of these small, worm-like muscles on each hand. These muscles are unusual in that they do not attach to bone. Instead they attach proximally to the tendons of flexor digitorum profundus and distally to the extensor expansions.</p>
	<p><b>Interossei Dorsales Manus</b></p>	<p>In human anatomy, the dorsal interossei (DI) are four muscles in the back of the hand that act to abduct (spread) the index, middle, and ring fingers away from hand's midline (ray of middle finger) and assist in flexion at the knuckle joints and extension in the finger joints. The dorsal interossei abducts the index, middle, and ring fingers. The first dorsal interosseous is also able to rotate the index finger slightly at the metacarpophalangeal joint and assist adductor pollicis in thumb adduction</p>


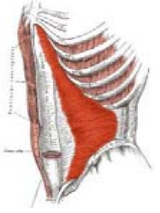


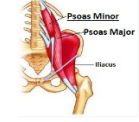


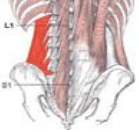
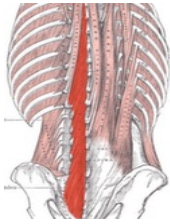
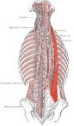
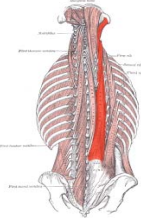
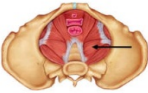
	<p><b>Lumbricales Manus</b></p>	<p>The lumbricals are intrinsic muscles of the hand that flex the metacarpophalangeal joints and extend the interphalangeal joints. There are four of these small, worm-like muscles on each hand. These muscles are unusual in that they do not attach to bone. Instead they attach proximally to the tendons of flexor digitorum profundus and distally to the extensor expansions.</p>
	<p><b>Flexor Digiti Minimi Brevis</b></p>	<p>The flexor digiti minimi brevis is a muscle in the hand that flexes the little finger. It lies in the same plane as the abductor digiti minimi, on its radial side. The flexor digiti minimi flexes the little finger.</p>
	<p><b>Abductor Digiti Minimi Manus</b></p>	<p>In human anatomy, the abductor digiti minimi (abductor minimi digiti, abductor digiti quinti, ADM) is a skeletal muscle situated on the ulnar border of the palm of the hand. It forms the ulnar border of the palm and its spindle-like shape defines the hypothenar eminence of the palm together with the skin, connective tissue, and fat surrounding it. Its main function is to pull the little finger away from the other fingers (i.e. abduction). It is a pure abductor of the little finger. It is possible that the muscle contribute to extension of the middle phalanx of the little finger through its connection to finger's extensor mechanism. It plays an important role when the hand is grasping large objects with outspread fingers.</p>
	<p><b>Interossei Palmaris</b></p>	<p>In human anatomy, the palmar or volar interossei (interossei volares in older literature) are three small, unipennate muscles in the hand that lie between the metacarpal bones and are attached to the index, ring, and little fingers. The palmar interosseous muscles adduct the fingers towards the middle finger. This is in contrast to the dorsal interossei, which abduct the fingers away from the middle finger. In addition (like dorsal interossei) they flex the finger at the metacarpophalangeal joint and extend the finger at the interphalangeal joint and thus assist the lumbricals. The palmar interossei, together with the dorsal interossei and the lumbricals, are active components of the finger's extensor mechanism. Fibers from some of the interossei contribute directly to the extensor hoods that wrap around the proximal phalanges while other fibers may contribute to the central tendon and lateral bands of the mechanism. All three intrinsic groups of muscles pass palmar to the axis of the metacarpophalangeal joints and therefore contribute to flexion there. Extension at the interphalangeal joints cannot be produced by the extensor digitorum alone, but active contraction of one of the three aforementioned intrinsic groups will because of their direct contribution to the extensor mechanism.</p>
	<p><b>Palmaris Brevis</b></p>	<p>Palmaris brevis is a thin, quadrilateral muscle, placed beneath the integument of the ulnar side of the hand. It acts to fold the skin of the hypothenar eminence transversally. It tenses the skin of the palm on the ulnar side during a grip action, and deepens the hollow of the palm. Pulls on skin over hypothenar eminence, deepening the cup of the palm and so improving grip</p>

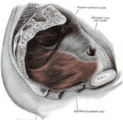
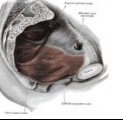

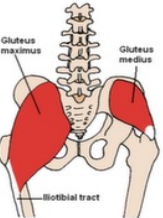
## MID TO LOW BACK, BUTTOCKS, PELVIS, AND ABDOMEN


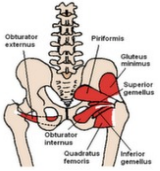
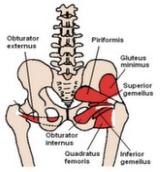
	<p style="text-align: center;"><b>Spinalis Thoracis</b></p>	<p>Laterally: Flex the head and neck to the same side. Bilaterally: Extend the vertebral column. The spinalis is a portion of the erector spinae, a bundle of muscles and tendons, located nearest to the spine. It is divided into three parts: Spinalis dorsi, spinalis cervicis, and spinalis capitis. Spinalis dorsi, the medial continuation of the sacrospinalis, is scarcely separable as a distinct muscle. It is situated at the medial side of the longissimus dorsi, and is intimately blended with it; it arises by three or four tendons from the spinous processes of the first two lumbar and the last two thoracic vertebrae: these, uniting, form a small muscle which is inserted by separate tendons into the spinous processes of the upper thoracic vertebrae, the number varying from four to eight. It is intimately united with the semispinalis dorsi, situated beneath it. Spinalis cervicis, or spinalis colli, is an inconstant muscle, which arises from the lower part of the ligamentum nuchæ, the spinous process of the seventh cervical, and sometimes from the spinous processes of the first and second thoracic vertebrae, and is inserted into the spinous process of the axis, and occasionally into the spinous processes of the two cervical vertebrae below it. Spinalis capitis (biventer cervicis) is usually inseparably connected with the semispinalis capitis.</p>
	<p style="text-align: center;"><b>Longissimus Thoracis</b></p>	<p>Laterally: Flex the head and neck to the same side. Bilaterally: Extend the vertebral column. LONGISSIMUS THORACIS: The longissimus thoracis is the intermediate and largest of the continuations of the sacrospinalis. In the lumbar region, where it is as yet blended with the iliocostalis lumborum, some of its fibers are attached to the whole length of the posterior surfaces of the transverse processes and the accessory processes of the lumbar vertebrae, and to the anterior layer of the lumbodorsal fascia. In the thoracic region, it is inserted, by rounded tendons, into the tips of the transverse processes of all the thoracic vertebrae, and by fleshy processes into the lower nine or ten ribs between their tubercles and angles. LONGISSIMUS CERVICIS: The longissimus cervicis (transversalis cervicis), situated medial to the longissimus dorsi, arises by long, thin tendons from the summits of the transverse processes of the upper four or five thoracic vertebrae, and is inserted by similar tendons into the posterior tubercles of the transverse processes of the cervical vertebrae from the second to the sixth inclusive. LONGISSIMUS CAPITIS: The longissimus capitis (trachelomastoid muscle) lies medial to the longissimus cervicis, between it and the semispinalis capitis. It arises by tendons from the transverse processes of the upper four or five thoracic vertebrae, and the articular processes of the lower three or four cervical vertebrae, and is inserted into the posterior margin of the mastoid process, beneath the splenius capitis and sternocleidomastoideus. It is almost always crossed by a tendinous intersection near its insertion.</p>
	<p style="text-align: center;"><b>Levator Costorum</b></p>	<p>The Levatores costarum, twelve in number on either side, are small tendinous and fleshy bundles, which arise from the ends of the transverse processes of the seventh cervical and upper eleven thoracic vertebrae. They pass obliquely downward and laterally, like the fibers of the Intercostales externi, and each is inserted into the outer surface of the rib immediately below the vertebra from which it takes origin, between the tubercle and the angle (Levatores costarum breves). Each of the four lower muscles divides into two fasciculi, one of which is inserted as above described; the other passes down to the second rib below its origin (Levatores costarum longi). Their role in normal inspiration, if any, is uncertain. They may play a role in vertebral movement and/or proprioception.</p>

	<p><b>Serratus Posterior</b></p>	<p>The serratus posterior superior is a thin, quadrilateral muscle, situated at the upper and back part of the thorax, deep to the rhomboid muscles. It arises by a thin and broad aponeurosis from the lower part of the ligamentum nuchae, from the spinous processes of the seventh cervical and upper two or three thoracic vertebrae and from the supraspinal ligament. Inclining downward and lateralward it becomes muscular, and is inserted, by four fleshy digitations, into the upper borders of the second, third, fourth, and fifth ribs, a little beyond their angles. The function of serratus posterior superior is to elevate second to fifth ribs, which aids deep inspiration.</p> <p>The serratus posterior inferior draws the lower ribs backward and downward to assist in rotation and extension of the trunk. This movement of the ribs also contributes to forced expiration of air from the lungs.</p>
	<p><b>Diaphragm</b></p>	<p>In human anatomy, the thoracic diaphragm, or simply the diaphragm, is a sheet of internal skeletal muscle that extends across the bottom of the rib cage. The diaphragm separates the thoracic cavity containing the heart and lungs, from the abdominal cavity and performs an important function in respiration: as the diaphragm contracts, the volume of the thoracic cavity increases and air is drawn into the lungs. The diaphragm functions in breathing. During inhalation, the diaphragm contracts and moves in the inferior direction, thus enlarging the volume of the thoracic cavity (the external intercostal muscles also participate in this enlargement). This reduces intra:thoracic pressure: In other words, enlarging the cavity creates suction that draws air into the lungs. Cavity expansion happens in two extremes, along with intermediary forms. When the lower ribs are stabilized and the central tendon of the diaphragm is mobile, a contraction brings the insertion (central tendon) towards the origins and pushes the lower cavity towards the pelvis, allowing the thoracic cavity to expand downward. This is often called belly breathing. When the central tendon is stabilized and the lower ribs are mobile, a contraction lifts the origins (ribs) up towards the insertion (central tendon) which works in conjunction with other muscles to allow the ribs to slide and the thoracic cavity to expand laterally and upwards. When the diaphragm relaxes, air is exhaled by elastic recoil of the lung and the tissues lining the thoracic cavity. Assisting this function with muscular effort (called forced exhalation) involves the internal intercostal muscles used in conjunction with the abdominal muscles, which act as an antagonist paired with the diaphragm's contraction. The diaphragm is also involved in non:respiratory functions, helping to expel vomit, feces, and urine from the body by increasing intra:abdominal pressure, and preventing acid reflux by exerting pressure on the esophagus as it passes through the esophageal hiatus. In some non:human animals, the diaphragm is not crucial for breathing: a cow, for instance, can survive fairly asymptotically with diaphragmatic paralysis as long as no massive aerobic metabolic demands are made of it.</p>
	<p><b>Pyramidalis</b></p>	<p>The pyramidalis is a small and triangular muscle, anterior to the Rectus abdominis, and contained in the rectus sheath. Inferiorly, it attaches to the pelvis in two places: the pubic symphysis and pubic crest, arising by tendinous fibers from the anterior part of the pubis and the anterior pubic ligament. Superiorly, the fleshy portion of the muscle passes upward, diminishing in size as it ascends, and ends by a pointed extremity which is inserted into the linea alba, midway between the umbilicus and pubis. Therefore, when contracting, it has the function of tensing the linea alba.</p>
	<p><b>Obliquus Externus Abdominis</b></p> <p><b>Obliquus Internus Abdominis</b></p>	<p>The external oblique muscle (of the abdomen) (also external abdominal oblique muscle) is the largest and the most superficial (outermost) of the three flat muscles of the lateral anterior abdomen. The external oblique functions to pull the chest downwards and compress the abdominal cavity, which increases the intra:abdominal pressure as in a valsalva maneuver. It also has limited actions in both flexion and rotation of the vertebral column. One side of the obliques contracting can create lateral flexion. It also contributes in compression of abdomen.</p>

	<p><b>Rectus Abdominis</b></p>	<p>The rectus abdominis muscle, also known as the :abs and lower abdominals,; is a paired muscle running vertically on each side of the anterior wall of the human abdomen, as well as that of some other mammals. There are two parallel muscles, separated by a midline band of connective tissue called the linea alba (:white line:). The rectus abdominis is an important postural muscle. It is responsible for flexing the lumbar spine, as when doing a so:called :crunch: sit up. The rib cage is brought up to where the pelvis is when the pelvis is fixed, or the pelvis can be brought towards the rib cage (posterior pelvic tilt) when the rib cage is fixed, such as in a leg:hip raise. The two can also be brought together simultaneously when neither is fixed in space. The rectus abdominis assists with breathing and plays an important role in respiration when forcefully exhaling, as seen after exercise as well as in conditions where exhalation is difficult such as emphysema. It also helps in keeping the internal organs intact and in creating intra:abdominal pressure, such as when exercising or lifting heavy weights, during forceful defecation or parturition (childbirth).</p>
	<p><b>Transverse Abdominis</b></p>	<p>The transversus abdominis muscle (TVA), also known as the transverse abdominus, transversalis muscle and transverse abdominal muscle, is a muscle layer of the anterior and lateral (front and side) abdominal wall which is deep to (layered below) the internal oblique muscle. It is thought to be a significant component of the core. he transversus abdominis helps to compress the ribs and viscera, providing thoracic and pelvic stability. This is explained further here. The transversus abdominis also helps pregnant women deliver their child.</p>
	<p><b>Iliacus</b></p>	<p>The iliacus is a flat, triangular muscle which fills the iliac fossa. In open:chain movements, as part of the iliopsoas, the iliacus is important for lifting (flexing) the femur forward. In closed:chain movements, the iliopsoas bends the trunk forward and can lift the trunk from a lying posture (i.e. sit:ups) because the psoas major crosses several vertebral joints and the sacroiliac joint. From its origin in the lesser pelvis the iliacus acts exclusively on the hip joint.</p>
	<p><b>Psoas Major</b></p>	<p>The psoas major is a long fusiform muscle located on the side of the lumbar region of the vertebral column and brim of the lesser pelvis. It joins the iliacus muscle to form the iliopsoas. The psoas major is divided into a superficial and deep part. The deep part originates from the transverse processes of lumbar vertebrae L:V. The superficial part originates from the lateral surfaces of the last thoracic vertebra, lumbar vertebrae L:IV, and from neighboring intervertebral discs. The lumbar plexus lies between the two layers.</p> <p>As part of the iliopsoas, psoas major contributes to flexion and external rotation in the hip joint. On the lumbar spine, unilateral contraction bends the trunk laterally, while bilateral contraction raises the trunk from its supine position. It forms part of a group of muscles called the hip flexors, whose action is primarily to lift the upper leg towards the body when the body is fixed or to pull the body towards the leg when the leg is fixed. For example, when doing a situp that brings the torso (including the lower back) away from the ground and towards the front of the leg, the hip flexors (including the iliopsoas) will flex the spine upon the pelvis. Owing to the frontal attachment on the vertebrae, rotation of the spine will stretch the psoas.</p>
		

	<p><b>Quadratus Lumborum</b></p>	<p>The Quadratus lumborum is a muscle in the lower back. It is irregular and quadrilateral in shape, and broader below than above. The quadratus lumborum can perform four actions: Lateral flexion of vertebral column, with ipsilateral contraction; Extension of lumbar vertebral column, with bilateral contraction; Fixes the 12th rib during forced expiration; Elevates the Ilium (bone), with ipsilateral contraction</p>
	<p><b>Multifidus</b></p>	<p>muscle consists of a number of fleshy and tendinous fasciculi, which fill up the groove on either side of the spinous processes of the vertebrae, from the sacrum to the axis. The multifidus is a very thin muscle. Deep in the spine, it spans three joint segments, and works to stabilize the joints at each segmental level. The stiffness and stability makes each vertebra work more effectively, and reduces the degeneration of the joint structures. These fasciculi arise: in the sacral region: from the back of the sacrum, as low as the fourth sacral foramen, from the aponeurosis of origin of the Sacrospinalis, from the medial surface of the posterior; superior iliac spine, and from the posterior sacroiliac ligaments; in the lumbar region: from all the mamillary processes; in the thoracic region: from all the transverse processes; in the cervical region: from the articular processes of the lower four vertebrae; Each fasciculus, passing obliquely upward and medialward, is inserted into the whole length of the spinous process of one of the vertebrae above. These fasciculi vary in length: the most superficial, the longest, pass from one vertebra to the third or fourth above; those next in order run from one vertebra to the second or third above; while the deepest connect two contiguous vertebrae. The multifidus lies deep relative to the Spinal Erectors, Transverse Abdominus, Abdominal internal oblique muscle and Abdominal external oblique muscle.</p>
	<p><b>Iliocostalis Lumborum</b></p>	<p>The iliocostalis is the muscle immediately lateral to the longissimus that is the nearest to the furrow that separates the epaxial muscles from the hypaxial. It lies very deep to the fleshy portion of the serratus ventralis (serratus anterior). Unilaterally: Flex the head and neck to the same side. Bilaterally: Extend the vertebral column.</p>
	<p><b>Longissimus Lumborum</b></p>	<p>Laterally: Flex the head and neck to the same side. Bilaterally: Extend the vertebral column. LONGISSIMUS THORACIS: The longissimus thoracis is the intermediate and largest of the continuations of the sacrospinalis. In the lumbar region, where it is as yet blended with the iliocostalis lumborum, some of its fibers are attached to the whole length of the posterior surfaces of the transverse processes and the accessory processes of the lumbar vertebrae, and to the anterior layer of the lumbodorsal fascia. In the thoracic region, it is inserted, by rounded tendons, into the tips of the transverse processes of all the thoracic vertebrae, and by fleshy processes into the lower nine or ten ribs between their tubercles and angles. LONGISSIMUS CERVICIS: The longissimus cervicis (transversalis cervicis), situated medial to the longissimus dorsi, arises by long, thin tendons from the summits of the transverse processes of the upper four or five thoracic vertebrae, and is inserted by similar tendons into the posterior tubercles of the transverse processes of the cervical vertebrae from the second to the sixth inclusive. LONGISSIMUS CAPITIS: The longissimus capitis (trachelomastoid muscle) lies medial to the longissimus cervicis, between it and the semispinalis capitis. It arises by tendons from the transverse processes of the upper four or five thoracic vertebrae, and the articular processes of the lower three or four cervical vertebrae, and is inserted into the posterior margin of the mastoid process, beneath the splenius capitis and sternocleidomastoideus. It is almost always crossed by a tendinous intersection near its insertion.</p>
	<p><b>Coccygeus</b></p>	<p>The Coccygeus is a muscle of the pelvic floor, located posterior to levator ani and anterior to the sacrospinous ligament. It is a triangular plane of muscular and tendinous fibers, arising by its apex from the spine of the ischium and sacrospinous ligament, and inserted by its base into the margin of the coccyx and into the side of the lowest piece of the sacrum. In combination with the levator ani, it forms the pelvic diaphragm. It assists the levator ani and piriformis in closing in the back part of the outlet of the pelvis.</p>

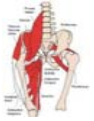	<p><b>Pubococcygeus</b></p>	<p>The pubococcygeus muscle or PC muscle is a hammock-like muscle, found in both sexes, that stretches from the pubic bone to the coccyx (tail bone) forming the floor of the pelvic cavity and supporting the pelvic organs. It is part of the levator ani group of muscles. The Pubococcygeus muscle controls urine flow and contracts during orgasm. It also aids in childbirth as well as core stability. A strong pubococcygeus muscle has also been linked to a reduction in urinary incontinence and proper positioning of the baby's head during childbirth</p>
	<p><b>Iliococcygeus</b></p>	<p>The Iliococcygeus arises from the inner side of the ischium and from the posterior part of the tendinous arch of the obturator fascia, and is attached to the coccyx and anococcygeal raphe; it is usually thin, and may fail entirely, or be largely replaced by fibrous tissue. It is part of the levator ani group of muscles. An accessory slip at its posterior part is sometimes named the Iliosacralis.</p>
	<p><b>Cremaster</b></p>	<p>The cremaster muscle is a muscle that covers the testis and the spermatic cord. raise and lower the scrotum</p>
	<p><b>Gluteus Medius</b></p>	<p>The gluteus medius (or glutæus medius), one of the three gluteal muscles, is a broad, thick, radiating muscle, situated on the outer surface of the pelvis. Its posterior third is covered by the gluteus maximus, its anterior two-thirds by the gluteal aponeurosis, which separates it from the superficial fascia and integument.</p> <p>With the leg in neutral (straightened), the gluteus medius and gluteus minimus function together to pull the thigh away from midline, or :abduct: the thigh. During gait, these two muscles function principally in supporting the body on one leg, in conjunction with the tensor fascia latae, to prevent the pelvis from dropping to the opposite side. Additionally, with the hip flexed the gluteus medius and minimus internally rotate the thigh. With the hip extended, the gluteus medius and gluteus minimus externally rotate the thigh</p> <p>The gluteus maximus (also known as glutæus maximus or, collectively with the gluteus medius and minimus, the glutes) is the largest and most superficial of the three gluteal muscles. It makes up a large portion of the shape and appearance of the hips. It is a narrow and thick fleshy mass of a quadrilateral shape, and forms the prominence of the nates. Its large size is one of the most characteristic features of the muscular system in humans, [ connected as it is with the power of maintaining the trunk in the erect posture. Other primates have much flatter hips. The muscle is remarkably coarse in structure, being made up of fasciculi lying parallel with one another, and collected together into large bundles separated by fibrous septa. When the gluteus maximus takes its fixed point from the pelvis, it extends the acetabulofemoral joint and brings the bent thigh into a line with the body. Taking its fixed point from below, it acts upon the pelvis, supporting it and the trunk upon the head of the femur; this is especially obvious in standing on one leg. Its most powerful action is to cause the body to regain the erect position after stopping, by drawing the pelvis backward, being assisted in this action by the biceps femoris (long head), semitendinosus, semimembranosus, and adductor magnus. The gluteus maximus is a tensor of the fascia lata, and by its connection with the iliotibial band steadies the femur on the articular surfaces of the tibia during standing, when the extensor muscles are relaxed. The lower part of the muscle also acts as an adductor and external rotator of the limb. The upper fibers act as abductors of the hip joints.</p>

	<p><b>Gluteus Minimus</b></p>	<p>The gluteus minimus (or glutæus minimus), the smallest of the three gluteal muscles, is situated immediately beneath the gluteus medius. The gluteus medius and gluteus minimus abduct the thigh, when the limb is extended, and are principally called into action in supporting the body on one limb, in conjunction with the Tensor fasciæ latæ. Their anterior fibers, by drawing the greater trochanter forward, rotate the thigh inward, in which action they are also assisted by the Tensor fasciæ latæ. Additionally, with the hip flexed the gluteus medius and minimus externally rotate the thigh. With the hip extended, the gluteus medius and gluteus minimus internally rotate the thigh</p>
	<p><b>Piriformis</b></p>	<p>The piriformis (from Latin piriformis = :pear shaped:) is a muscle in the gluteal region of the lower limb. It is one of the six muscles in the lateral rotator group. The piriformis muscle is part of the lateral rotators of the hip, along with the quadratus femoris, gemellus inferior, gemellus superior, obturator externus, and obturator internus. The piriformis laterally rotates the femur with hip extension and abducts the femur with hip flexion. Abduction of the flexed thigh is important in the action of walking because it shifts the body weight to the opposite side of the foot being lifted, which keeps us from falling. The action of the lateral rotators can be understood by crossing your legs to rest an ankle on the knee of the other leg. This causes the femur to rotate and point the knee laterally. The lateral rotators also oppose medial rotation by the gluteus medius and gluteus minimus. When the hip is flexed to 90 degrees, piriformis abducts the femur at the hip</p>
	<p><b>Gemellus Inferior</b></p> <hr/> <p><b>Gemellus Superior</b></p>	<p>The inferior gemellus muscle is a muscle of the human body. The Gemelli are two small muscular fasciculi, accessories to the tendon of the Obturator internus which is received into a groove between them. The Gemellus inferior arises from the upper part of the tuberosity of the ischium, immediately below the groove for the Obturator internus tendon. It blends with the lower part of the tendon of the Obturator internus, and is inserted with it into the medial surface of the greater trochanter. Rarely absent. Rotates laterally thigh</p>

## LEGS & FEET







	<p><b>Tensor Fascia Lata</b></p>	<p>The tensor fasciae latae is a hip flexor and abductor muscle, meaning it assists in moving the hip forward and outward. Rotating the hips inward is another action the TFL muscle does. The basic functional movement of tensor fascia latae is walking. The tensor fascia lata is heavily utilized in horse riding, hurdling and water skiing. Some problems that arise when this muscle is tight or shortened are pelvic imbalances that lead to pain in hips, as well as pain in the lower back and lateral area of knees</p>
	<p><b>Rectus Femoris</b></p>	<p>The neurons for voluntary thigh contraction originate near the summit of the medial side of the precentral gyrus (the primary motor area of the brain). These neurons send a nerve signal that is carried by the corticospinal tract down the brainstem and spinal cord. The signal starts with the upper motor neurons carrying the signal from the precentral gyrus down through the internal capsule, through the cerebral peduncle, and into the medulla. In the medullary pyramid, the corticospinal tract decussates and becomes the lateral corticospinal tract. The rectus femoris, sartorius, and iliopsoas are the flexors of the thigh at the hip. The rectus femoris is a weaker hip flexor when the knee is extended because it is already shortened and thus suffers from active insufficiency; the action will recruit more iliacus, psoas major, tensor fasciae latae, and the remaining hip flexors than it will the rectus femoris.</p>
	<p><b>Pectineus</b></p>	<p>It is one of the muscles primarily responsible for hip flexion. It also adducts the thigh.</p>
	<p><b>Adductor Brevis</b></p>	<p>The adductor brevis is a muscle in the thigh situated immediately behind the pectineus and adductor longus. It belongs to the adductor muscle group. The main function of the adductor brevis is to pull the thigh medially.[1] The adductor brevis and the rest of the adductor muscle group is also used to stabilize left to right movements of the trunk, when standing on both feet, or to balance when standing on a moving surface. The adductor muscle group is used pressing the thighs together to ride a horse, and kicking with the inside of the foot in soccer or swimming. Last, they contribute to flexion of the thigh when running or against resistance (squats, jumping, etc)</p>
	<p><b>Adductor Longus</b></p>	<p>In the human body, the adductor longus is a skeletal muscle located in the thigh. One of the adductor muscles of the hip, its main function is to adduct the thigh and it is innervated by the obturator nerve. Its main actions is to adduct and laterally rotate the femur; it can also produce some degree of flexion/anteversion.</p>

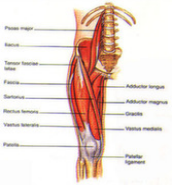


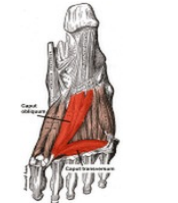
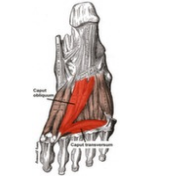




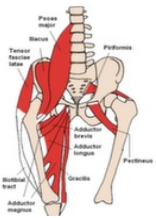




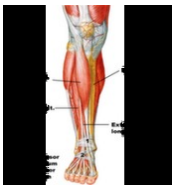
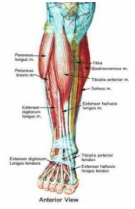

**Gracilis**






The muscle adducts, medially rotates, and flexes the hip as above, and also aids in flexion of the knee.

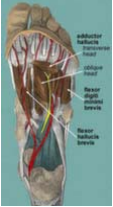



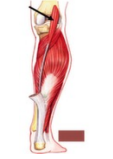
	<p><b>Sartorius</b></p>	<p>The sartorius muscle are the longest muscle in the human body – is a long thin muscle that runs down the length of the thigh in the anterior compartment. Its upper portion forms the lateral border of the femoral triangle. The sartorius muscle assists in flexing, weak abduction and lateral rotation of hip, and flexion of knee.[1] Looking at the bottom of one's foot, as if checking to see if one had stepped in gum, demonstrates all four actions of sartorius.</p>
	<p><b>Obturator Externus</b></p>	<p>The obturator externus muscle is a flat, triangular muscle, which covers the outer surface of the anterior wall of the pelvis. Obturator externus act as lateral rotator hip joint. As a short muscle around hip joint it stabilizes hip joint as a postural muscle.</p>
	<p><b>Quadratus Femoris</b></p>	<p>The quadratus femoris is a flat, quadrilateral skeletal muscle. Located on the posterior side of the hip joint, it is a strong external rotator and adductor of the thigh,[2] but also acts to stabilize the femoral head in the Acetabulum.</p>
	<p><b>Obturator Internus</b></p>	<p>It functions to help laterally rotate femur with hip extension and abduct femur with hip flexion, as well as to steady the femoral head in the acetabulum.</p>
	<p><b>Biceps Femoris</b></p>	<p>The biceps femoris is a muscle of the posterior (the back) thigh. As its name implies, it has two parts, one of which (the long head) forms part of the hamstrings muscle group. Both heads of the biceps femoris perform knee flexion. Since the long head originates in the pelvis it is also involved in hip extension. The long head of the biceps femoris is a weaker knee flexor when the hip is extended (because of active insufficiency). For the same reason the long head is a weaker hip extender when the knee is flexed. When the knee is semi-flexed, the biceps femoris in consequence of its oblique direction rotates the leg slightly outward.</p>
	<p><b>Vastus Medialis</b></p>	<p>The Vastus Medialis is one of five muscles that reside in the anterior compartment of the thigh. The vasti muscles appear to act largely in a co:ordinated manner throughout the control of knee extension. The vastus medialis contributes to correct tracking of the patella and characteristics of the vastus medialis, including its angle of insertion, correlate with presence of patellofemoral joint pain.</p>






	<p><b>Vastus Lateralis</b></p>	<p>The Vastus lateralis is the largest part of the quadriceps femoris.</p>
	<p><b>Vastus Intermedius</b></p>	<p>The vastus intermedius arises from the front and lateral surfaces of the body of the femur in its upper two-thirds, sitting under the rectus femoris muscle and from the lower part of the lateral intermuscular septum. Its fibers end in a superficial aponeurosis, which forms the deep part of the quadriceps femoris tendon. The vastus medialis and vastus intermedius appear to be inseparably united, but when the rectus femoris has been reflected a narrow interval will be observed extending upward from the medial border of the patella between the two muscles, and the separation may be continued as far as the lower part of the intertrochanteric line, where, however, the two muscles are frequently continuous. Due to being the deeper middle-most of the quadriceps muscle group, the intermedius is the most difficult to stretch once maximum knee flexion is attained. It cannot be further stretched by hip extension as the rectus femoris can, nor is it accessible to manipulate with massage therapy to stretch the fibres sideways as the vastus lateralis and vastus medialis are.</p>
	<p><b>Articularis Genu</b></p>	<p>Articularis genu pulls the suprapatellar bursa superiorly during extension of the knee and prevents impingement of the synovial membrane between the patella and the femur.</p>
	<p><b>Adductor Hallucis Oblique Head</b></p>	<p>The Adductor hallucis (Adductor obliquus hallucis) arises by two heads—oblique and transverse and is responsible for adducting the big toe. It has two heads, both are innervated by the lateral plantar nerve. The oblique head is a large, thick, fleshy mass, crossing the foot obliquely and occupying the hollow space under the first, second, third and fourth metatarsal bones. It arises from the bases of the second, third, and fourth metatarsal bones, and from the sheath of the tendon of the Peronæus longus, and is inserted, together with the lateral portion of the Flexor hallucis brevis, into the lateral side of the base of the first phalanx of the great toe.</p>
	<p><b>Adductor Hallucis Transverse Head</b></p>	<p>The Adductor hallucis (Adductor obliquus hallucis) arises by two heads—oblique and transverse and is responsible for adducting the big toe. It has two heads, both are innervated by the lateral plantar nerve. The transverse head (Transversus pedis) is a narrow, flat fasciculus which arises from the plantar metatarsophalangeal ligaments of the third, fourth, and fifth toes (sometimes only from the third and fourth), and from the transverse ligament of the metatarsus. It is inserted into the lateral side of the base of the first phalanx of the great toe, its fibers blending with the tendon of insertion of the oblique head.</p>

	<b>Adductor Digiti Minimi Pedis</b>	<p>The abductor digiti minimi (abductor minimi digiti, abductor digiti quinti) is a muscle which lies along the lateral (outer) border of the foot, and is in relation by its medial margin with the lateral plantar artery, vein and nerves. Its function is flexion and abduction of the first (little) toe at the metatarsophalangeal joint</p>
	<b>Adductor Digiti Pedis</b>	<p>Its function is flexion and abduction of the second toe at the metatarsophalangeal joint</p>
		<p>Its function is flexion and abduction of the third (middle) toe at the metatarsophalangeal joint</p>
		<p>Its function is flexion and abduction of the fourth toe at the metatarsophalangeal joint</p>
<p>Its function is flexion and abduction of the fifth (big) toe at the metatarsophalangeal joint</p>		
	<b>Adductor Hallucis</b>	<p>The Adductor hallucis (Adductor obliquus hallucis) arises by two heads—oblique and transverse and is responsible for adducting the big toe. It has two heads, both are innervated by the lateral plantar nerve. Oblique head: The oblique head is a large, thick, fleshy mass, crossing the foot obliquely and occupying the hollow space under the first, second, third and fourth metatarsal bones. It arises from the bases of the second, third, and fourth metatarsal bones, and from the sheath of the tendon of the Peronæus longus, and is inserted, together with the lateral portion of the Flexor hallucis brevis, into the lateral side of the base of the first phalanx of the great toe. Transverse head: The transverse head (Transversus pedis) is a narrow, flat fasciculus which arises from the plantar metatarsophalangeal ligaments of the third, fourth, and fifth toes (sometimes only from the third and fourth), and from the transverse ligament of the metatarsus. It is inserted into the lateral side of the base of the first phalanx of the great toe, its fibers blending with the tendon of insertion of the oblique head.</p>
	<b>Adductor Magnus</b>	<p>The adductor magnus is a powerful adductor of the thigh, made especially active when the legs are moved from a wide spread position to one in which the legs parallel each other. The part attached to the linea aspera acts as a lateral rotator. The part which reaches the medial epicondyle acts as a medial rotator when the leg is rotated outwards and flexed, and also acts to extend the hip joint.</p>
	<b>Extensor Digitorum Brevis</b>	<p>The extensor digitorum brevis muscle (sometimes EDB) is a muscle on the upper surface of the foot that helps extend digits 2 through 4</p>
	<b>Extensor Digitorum Longus</b>	<p>The Extensor digitorum longus is a pennate muscle, situated at the lateral part of the front of the leg. Extension of toes and dorsiflexion of ankle</p>

	<p><b>Tibialis Anterior</b></p>	<p>In human anatomy, the tibialis anterior is a muscle that originates in the upper two-thirds of the lateral (outside) surface of the tibia and inserts into the first cuneiform and first metatarsal bones of the foot. Its acts to dorsiflex and invert the foot. This muscle is mostly located near the shin. The tibialis anterior muscle is the most medial muscle of the anterior compartment of the leg. The tibialis anterior is responsible for dorsiflexing and inverting the foot. The muscle has two origins, one being the lateral tibial condyle and the other being the upper lateral surface of the tibia, and inserts on the medial surface of the medial cuneiform and adjoining part of base of the first metatarsal of the foot allowing the toe to be pulled up and held in a locked position. It also allows for the ankle to be inverted giving the ankle horizontal movement allowing for some cushion if the ankle were to be rolled. It is innervated by the deep peroneal nerve and acts as both an antagonist and a synergist of the tibialis posterior. However, the most accurate antagonist of the tibialis anterior is the peroneus longus. The tibialis anterior aides in the activities of walking, running, hiking, kicking a ball, or any activity that requires moving the leg or keeping the leg vertical. It functions to stabilize the ankle as the foot hits the ground during the contact phase of walking (eccentric contraction) and acts later to pull the foot clear of the ground during the swing phase (concentric contraction). It also functions to 'lock' the ankle, as in toe:kicking a ball, when held in an isometric contraction. Antagonists are plantar:flexors of the posterior compartment such as soleus and gastrocnemius. Essentially, the movements of tibialis anterior are dorsiflexion and inversion of the ankle. However, actions of tibialis anterior are dependent on whether the foot is weight bearing or not (closed or open kinetic chain). When the foot is on the ground the muscle helps to balance the leg and talus on the other tarsal bones so that the leg is kept vertical even when walking on uneven ground.</p>
	<p><b>Extensor Hallucis Longus</b></p>	<p>The Extensor hallucis longus is a thin muscle, situated between the Tibialis anterior and the Extensor digitorum longus that functions to extend the big toe, dorsiflex the foot, and assists with foot eversion and inversion. Extends the big toe and assists in dorsiflexion of the foot at the ankle. Also is a weak evertor/ inverter</p>
	<p><b>Peroneus Longus</b></p>	<p>The fibularis brevis muscle (or peroneus brevis in British English) lies under cover of the fibularis longus, and is a shorter and smaller muscle. The muscle assists in weak plantarflexion and eversion of the foot.</p> <p>In human anatomy, the fibularis longus (also known as peroneus longus) is a superficial muscle in the lateral compartment of the leg, and acts to evert and plantar flex the ankle. The muscle, the longest and most superficial of the three fibularis muscles, is attached proximally to the head of the fibula and its 'belly' runs down most of this bone. It becomes a tendon that goes posteriorly around the lateral malleolus of the ankle, then continues under the foot to attach to the medial cuneiform and first metatarsal. The fibularis longus and brevis muscles plantar:flex the foot, in conjunction with the tibialis posterior, antagonizing the tibialis anterior and fibularis tertius, which are dorsi:flexors of the foot. The fibularis longus also everts the sole of the foot, and from the oblique direction of the tendon across the sole of the foot is an important agent in the maintenance of the transverse arch. This is especially the case in standing upon one leg, when the tendency of the superincumbent weight is to throw the leg medialward; the fibularis longus overcomes this tendency by drawing on the lateral side of the leg.</p>

	<p><b>Peroneus Tertius</b></p>	<p>The fibularis tertius (also known as peroneus tertius) is a muscle of the human body located in the lower limb. The muscle arises from the lower third of the anterior surface of the fibula (anterior compartment of lower leg); from the lower part of the interosseous membrane; and from an intermuscular septum between it and the peroneus brevis muscle. Its action is that of weak dorsiflexion of the ankle joint and to evert the foot at the ankle joint.</p>
	<p><b>Extensor Hallucis Brevis</b></p>	<p>The extensor hallucis brevis is a muscle on the top of the foot that helps to extend the big toe.</p>
	<p><b>Flexor Digitorum Brevis</b></p>	<p>The flexor digitorum brevis lies in the middle of the sole of the foot, immediately above the central part of the plantar aponeurosis, with which it is firmly united. Its deep surface is separated from the lateral plantar vessels and nerves by a thin layer of fascia.</p>
	<p><b>Flexor Digitorum Longus</b></p>	<p>The flexor digitorum longus is situated on the tibial side of the leg. At its origin it is thin and pointed, but it gradually increases in size as it descends. This muscle serves to curl the second, third, fourth, and fifth toes. Primary action is Flex digits</p>
	<p><b>Flexor Digitus Pedis</b></p>	<p>Flex and adduct the toe</p>

	<p><b>Flexor Hallucis Brevis</b></p>	<p>The Flexor hallucis brevis arises, by a pointed tendinous process, from the medial part of the under surface of the cuboid bone, from the contiguous portion of the third cuneiform, and from the prolongation of the tendon of the Tibialis posterior which is attached to that bone.</p>
	<p><b>Flexor Hallucis Longus</b></p>	<p>The Flexor hallucis longus is situated on the fibular side of the leg. It arises from the inferior two-thirds of the posterior surface of the body of the fibula, with the exception of 2.5 cm. at its lowest part; from the lower part of the interosseous membrane; from an intermuscular septum between it and the Peronæi, laterally, and from the fascia covering the Tibialis posterior, medially. Flexes all joints of the big toe, plantar flexion of the ankle joint!</p>
	<p><b>Gastrocnemius</b></p>	<p>In humans, the gastrocnemius muscle ; meaning :stomach of leg;, referring to the bulging shape of the calf) is a very powerful superficial bipennate muscle that is in the back part of the lower leg. It runs from its two heads just above the knee to the heel. The gastrocnemius is involved in standing, walking, running and jumping. Along with the soleus muscle it forms the calf muscle. Its function is plantar flexing the foot at the ankle joint and flexing the leg at the knee joint.</p>
	<p><b>Soleus</b></p>	<p>In humans and some other mammals, the soleus is a powerful muscle in the back part of the lower leg (the calf). It runs from just below the knee to the heel, and is involved in standing and walking. It is closely connected to the gastrocnemius muscle and some anatomists consider them to be a single muscle, the triceps surae. Its name is derived from the Latin word, :solea,; as in a :sole fish.: The action of the calf muscles, including the soleus, is plantarflexion of the foot (that is, they increase the angle between the foot and the leg). They are powerful muscles and are vital in walking, running, and dancing. The soleus specifically plays an important role in maintaining standing posture; if not for its constant pull, the body would fall forward. Also, in upright posture, it is responsible for pumping venous blood back into the heart from the periphery, and is often called the skeletal:muscle pump, peripheral heart or the sural (tricipital) pump. The Soleus is the most effective muscle for plantarflexion in a bent knee position. This is due to the fact that the gastrocnemius originates at on the femur, so bending the leg limits its effective tension. During regular movement (ie walking) the soleus is the primary muscle utilized for plantarflexion due to the slowtwitch fibers resisting fatigue.</p>
	<p><b>Plantaris</b></p>	<p>Plantaris is one of the superficial muscles of the posterior crural compartment of the leg. It is composed of a thin muscle belly and a long thin tendon. It is approximately 5:10 cm long and is absent in 7:10% of the human population. It is one of the plantar flexors in the posterior compartment of the leg, along with the gastrocnemius and soleus. The plantaris is considered an unimportant muscle and mainly acts with the gastrocnemius. Plantaris acts to weakly: plantarflex the ankle joint; flex the knee joint; Plantaris may also provide; proprioceptive feedback information to the central nervous system regarding the position of the foot. The unusually high density of proprioceptive receptor end organs supports this notion</p>

	<p><b>Popliteus</b></p>	<p>The popliteus muscle in the leg is used for unlocking the knees during walking/standing by laterally rotating the femur on the tibia (or medially rotating the tibia) during a closed chain movement (such as one with the foot in contact with the ground). The popliteus assists in flexing the leg upon the thigh; when the leg is flexed, it will rotate the tibia inward. It is especially called into action at the beginning of the act of bending the knee, in as much as it produces the slight inward rotation of the tibia, which is essential in the early stage of this movement. When the knee is in full extension; the femur slightly medially rotates on the tibia to lock the knee joint in place. Popliteus is often referred to as the :Key: to unlocking the knee since it begins knee flexion by laterally rotating the femur on the tibia. Popliteus is also attached to the lateral meniscus in the knee; and draws it posteriorly during knee flexion to prevent crushing the meniscus between the tibia and femur as the knee flexes.</p>
	<p><b>Quadratus Plantae</b></p>	<p>The quadratus plantæ (flexor accessorius) is separated from the muscles of the first layer by the lateral plantar vessels and nerve. It acts to aid in flexing the 2nd to 5th toes (offsetting the oblique pull of the flexor digitorum longus) and is one of the few muscles in the foot with no homolog in the hand. It arises by two heads, which are separated from each other by the long plantar ligament: the medial or larger head is muscular, and is attached to the medial concave surface of the calcaneus, below the groove which lodges the tendon of the flexor hallucis longus; the lateral head, flat and tendinous, arises from the lateral border of the inferior surface of the calcaneus, in front of the lateral process of its tuberosity, and from the long plantar ligament. The two portions join at an acute angle, and end in a flattened band which is inserted into the lateral margin and upper and under surfaces of the tendon of the flexor digitorum longus, forming a kind of groove, in which the tendon is lodged. It usually sends slips to those tendons of the Flexor digitorum longus which pass to the second, third, and fourth toes.</p>
	<p><b>Semimembranosus</b></p>	<p>The semimembranosus is a muscle in the back of the thigh. It is the most medial of the three hamstring muscles. The semimembranosus helps to extend (straighten) the hip joint and flex (bend) the knee joint. It also helps medially rotate the knee: the tibia medially rotates on the femur when the knee is flexed. Medially rotates the femur when the hip is extended. The muscle can also aid in counteracting the forward bending at the hip joint.</p>
	<p><b>Semitendinosus</b></p>	<p>The semitendinosus is a muscle in the back of the thigh; it is one of the hamstrings. The semitendinosus helps to extend (straighten) the hip joint and flex (bend) the knee joint. It also helps medially rotate the tibia on the femur when the knee is flexed and medially rotate the femur when the hip is extended. It counteracts forward bending at the hips as well.</p>
	<p><b>Tibialis Posterior</b></p>	<p>The tibialis posterior is the most central of all the leg muscles, and is located in the posterior compartment of the leg. It is the key stabilizing muscle of the lower leg. Blood is supplied to the muscle by the posterior tibial artery, and innervation is via the tibial nerve. As well as being a key muscle and tendon for stabilization, the tibialis posterior also contracts to produce inversion and assists in the plantar flexion of the foot at the ankle. The tibialis posterior has a major role in supporting the medial arch of the foot. Dysfunction of the tibialis posterior, including rupture of the tibialis posterior tendon, can lead to flat feet in adults, as well as a valgus deformity due to unopposed eversion when inversion is lost.</p>